



PATIENT

Dexter Barnes

SPECIES

Canine

BREED

Shih Tzu

SEX

Male Neutered

AGE

14.2 years

WEIGHT

9.6lbs

INTERPRETED BY

Maggie Machen Lamy,
DVM, DACVIM
(Cardiology)

IMAGING PERFORMED BY

Amanda Lacey-Crook

HOSPITAL NAME

Rivers Edge Pet
Medical Center

REFERRING VET

Dr. Gibson

INVOICE

22843

DATE

2/28/22

PRESENTING CLINICAL SIGNS

History: Pet recently has recovered from bronchitis. Owner states it is a different cough then what she recently had. Only one time pet had phlem. Synchronous femoral pulses with 2/6 left apical systolic heart murmur with suspected gallop sound. BP: 145mmHg.

-Current medications: Hydrocodone 1mg/ml- 1ml po q 12-24 as needed.

-Abnormal PE/Chem/CBC/UA Results: BUN 32, MCV 61.4, Platecrit 0.51

RADIOGRAPHIC FINDINGS *NOTE: Images submitted for supplemental cardiac information only.

Normal cardiac silhouette. No obvious evidence of CHF.

ECHOCARDIOGRAM FINDINGS

2D, m-mode, color flow and doppler imaging is available. Mild diffuse thickening of mitral valve leaflets with mild prolapse into the left atrial lumen. Mild mitral regurgitation with no left atrial dilation. Normal LV diameter with adequate myocardial function. The tricuspid valve appears normal with mild tricuspid regurgitation. Normal right heart. TR velocity indicative of early pulmonary arterial hypertension. The pulmonic and aortic valves are normal in morphology and mobility. Normal pulmonic and aortic outflow velocities with laminar flow. No obvious aortic or pulmonic insufficiency. No pericardial or pleural effusion noted. No obvious cardiac masses.

CARDIAC CHART

CANINE CARDIAC PARAMETERS	MR VMAX (m/s)	TR VMAX (m/s)	LA/AO (Boon method)	LA/AO (Heart Base; Swe)	FS (%)	EF (%)	EPSS (cm)
NORMAL PARAMETER	4.5-5.5	<2.7	1.3	<1.6	28-40	40-100	<0.6
PATIENT	5.3	3.0	1.3	1.1	55	88	0.2
CANINE CARDIAC PARAMETERS	HR (BPM)	AV VMAX (m/s)	PV MAX (m/s)	BODY WEIGHT (kg)	LA 2D short axis Base view (cm)	LVIDd Avg; 2D and m-mode short axis (cm)	LVIDs Avg; 2D and m-mode short axis (cm)
NORMAL PARAMETER	50-100	0.7-1.7	0.7-1.6	BELOW	BELOW	BELOW	BELOW
PATIENT	NM	0.8	0.7	4.4	1.4	1.9	0.9
*Normal chamber parameters expressed as a mean value (SD)				3	1.27 (5.3)	2.46 (2.46)	1.36 (5.5)
BODY WEIGHT DEPENDENT PARAMETERS				5	1.40 (4.5)	2.74 (5.2)	1.60 (4.7)
<i>*Note: All measurements based upon multi-modal images and methods. An average value is reported.</i>				10	1.50 (3.8)	3.27 (3.5)	2.06 (3.1)
				15	1.83 (2.0)	3.71 (2.4)	2.43 (2.1)
				20	2.02 (1.9)	4.14 (2.2)	2.80 (2.0)
				25	2.18 (2.4)	4.48 (2.9)	3.10 (2.5)
				30	2.33 (3.3)	4.83 (3.9)	3.39 (3.4)
				35	2.48 (4.3)	5.17 (5.0)	3.69 (4.5)
				40	2.62 (5.2)	5.48 (6.1)	3.96 (5.4)
				50	2.88 (7.1)	6.07 (8.3)	4.46 (7.4)

INTERPRETATION OF THE FINDINGS & FURTHER RECOMMENDATIONS

Chronic degenerative valve disease causing mild mitral and tricuspid regurgitation. Lack of significant left atrial enlargement indicates the current risk for complication is low. Mild pulmonary hypertension is noted, which is likely developing secondary to the cough/airway disease. No concurrent issues such as systolic dysfunction are noted in this study.



PATIENT

Dexter Barnes

SPECIES

Canine

BREED

Shih Tzu

SEX

Male Neutered

AGE

14.2 years

WEIGHT

9.6lbs

Given these findings, the cough is certainly non-cardiogenic in origin. Respiratory disease is considered most likely, and screening chest radiographs may be helpful as a baseline. If the cough is poorly controlled/progresses long term, this can certainly lead to worsening of PAH. Clinical signs of significant PAH include exertional dyspnea/collapse. Continued monitoring is advised. Cough control is recommended lifelong (hydrocodone, intermittent AI prednisone, fluoroquinolone for acute flare up, etc.).

In a dog without significant left atrial enlargement, no cardiac medications are clearly indicated. Assessment of progression in the future will help predict long term prognosis, which is highly variable at this stage (B1). Omega fatty acid supplementation and mild salt restriction may be of some long-term benefit. Monitor for development of a cough, labored breathing, exercise intolerance or collapse episodes.

Anesthetic risk is considered mild if needed. Cardiac protective drug choices (opioid/benzodiazepine premedication, propofol or alfaxalone induction, isoflurane gas) are recommended. **Pre-oxygenate for 5-10 minutes prior to induction.** Monitor for arrhythmias, hypotension, and hypoxia both intra and post-operatively and intervene as necessary. Mild IV fluid restriction is recommended to avoid fluid overload. Avoid heart rate stimulating drugs such as atropine unless clinically indicated.

Recommend conservative monitoring with a recheck echocardiogram in 6-12 months, sooner if any development of clinical signs.

INTERPRETED BY

Maggie Machen Lamy,
DVM, DACVIM
(Cardiology)

IMAGING PERFORMED BY

Amanda Lacey-Crook

HOSPITAL NAME

Rivers Edge Pet
Medical Center

REFERRING VET

Dr. Gibson

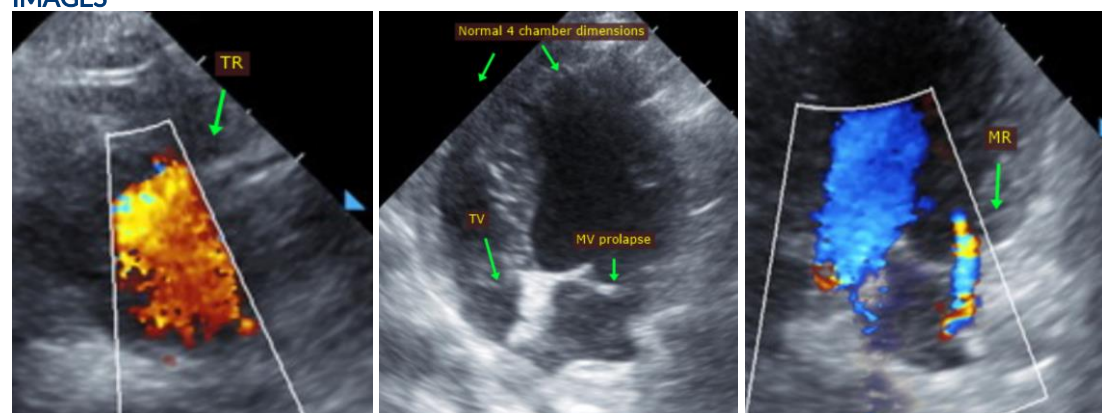
INVOICE

22843

DATE

2/28/22

IMAGES



The information and recommendations provided are based on the images presented by the referring veterinarian. No evaluation can be communicated regarding pathology that was not visible in the image/video clips provided.

Thank you for this referral. This report was generated using transcription software, and minor dictation errors may be present. If the clinical or image interpretation does not parallel your findings or if I can be of any further assistance, please contact me.

Maggie Machen Lamy, DVM
Diplomate of the American College of Veterinary Internal Medicine (Cardiology)
info@sonopath.com